medanta

THE EXCHANGE

Issue 44
November 2021

A Knowledge Sharing Initiative by Medanta

Medanta Now in Patna

Committed to medical excellence and patient care, Medanta recently launched Jay Prabha Medanta Super Specialty Hospital in Patna.



The hospital was inaugurated by Hon'ble Chief Minister of Bihar, Shri Nitish Kumar Ji in the presence of Deputy Chief Minister - Shri Tarkishore Prasad, Health Minister - Shri Mangal Pandey, and Principal Secretary, Department of Health - Shri Pratyaya Amrit.

Built on a culture of ethical and transparent medical practices, the hospital will strive to deliver affordable world-class healthcare services in an excellence driven patient-centric environment.

A blend of medical expertise, cutting-edge technology, and state-of-the-art infrastructure with a highly integrated and comprehensive information system, the hospital will endeavour to offer cohort-driven, multi-disciplinary approach to treatment across several specialities.

- Cardiology & cardiac surgery
- Neurology & neurosurgery
- Gastroenterology & hepatology
- Gastrosurgery
- Urology & Nephrology
- Orthopaedics & joint replacement
- Gynaecology
- Cancer
- Respiratory medicine
- Internal medicine
- Diabetes & endocrinology
- Dental sciences
- Critical care & anaesthesiology
- Radiology

THE EXCHANGE

Issue 44
November 2021

Jay Prabha Medanta Super Specialty Hospital is a clinical unit with an integrated holistic design. The hospital is spread across **7** acres, and is designed to accommodate **14** operating theatres, **500** beds and **112** critical care beds. It is led and managed by best-in-class doctors and has cutting edge technology and facilities designed to deliver world-class healthcare to the citizens of Bihar at affordable cost.

Dr Naresh Trehan
Chairman and
Managing Director
Medanta

"At Medanta, we strive to deliver world-class healthcare by establishing institutes of excellence that integrate medical care, teaching and research all while providing affordable medical services to patients. We also equip our hospitals with advanced medical technology and equipment, and diagnostic instruments with the aim of providing our patients with accurate diagnoses and effective treatments. Through Jay Prabha Medanta Super Speciality Hospital, we intend to address what we expect to be a sizeable healthcare demand from North East India, parts of Jharkhand and Nepal."

Shri Nitish Kumar Ji
Hon'ble Chief Minister, Bihar

"I am delighted to dedicate quality healthcare to citizens of Bihar through Jay Prabha Medanta Super Specialty Hospital. The hospital will offer technologically advanced treatment and be a new benchmark of healthcare in the state."

THE EXCHANGE

Issue 44
November 2021

TechByte

Leading Edge in Salvage of Non-functioning Arteriovenous Fistula

Maintaining arteriovenous (AV) access function is crucial to ensure quality of life of patients undergoing hemodialysis. There are two necessary factors for an arteriovenous fistula (AVF) to be usable as dialysis access. First, it must have adequate blood flow, and second, it must have a size that will allow cannulation.

Cephalic arch is the term given to the final arch of the cephalic vein before it joins the axillary vein to form the subclavian vein. Cephalic arch stenosis (CAS) causes repeated dysfunction and failure of arteriovenous access. Percutaneous transluminal angioplasty is the standard initial treatment for CAS, but its outcome is unsatisfactory.

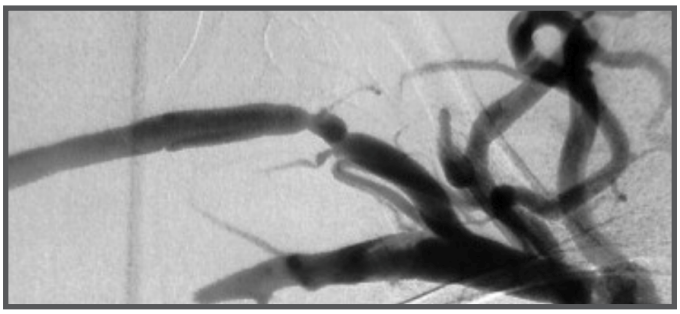

Critical Stenosis at Cephalic Arch

Satisfactory outcomes of stent graft placement for treating AV access outflow have been reported, especially in arteriovenous graft (AVG) outlet anastomosis stenosis. However, little is known about stent graft placement in CAS. In the following case study, we discuss the outcome of two patients on hemodialysis who had angioplasty failure and received the latest stent graft to treat CAS.

Prior to the procedure, a complete fistulogram was obtained under local anesthesia followed by digital subtraction venography, which showed cephalic arch lesions. We placed Covera stent graft over the cephalic arch, and it did not protrude into the axillary vein within 1 cm to avoid coverage of the axillary vein and preserve the chance of further outlet bypass.

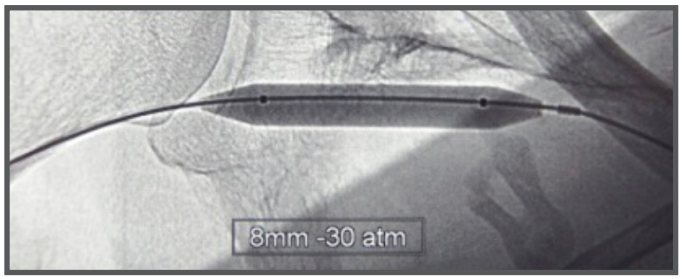

High Pressure Balloon Dilatation

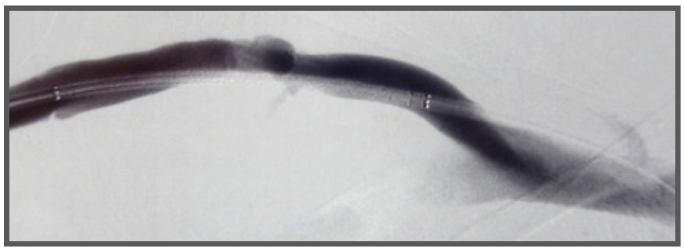

COVERA Stent in Position

Covera Vascular Covered Stent is a novel ePTFE covered stent designed for the treatment of stenosis in the venous outflow of AV Fistula.

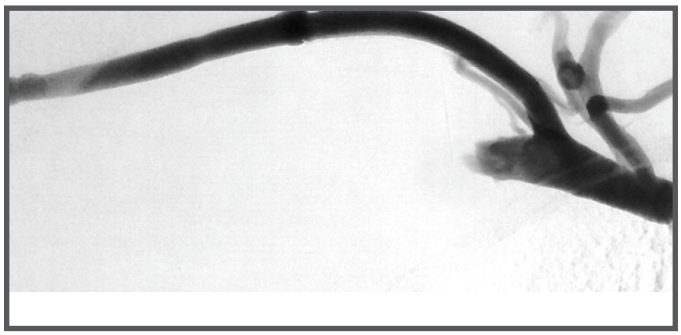

Final Completion Venogram

Technical success was defined as there was an adequate stent graft location and sufficient lesion coverage. And, clinical success was defined as there was restoration of normal function of AV access and improvement in symptoms.

In conclusion, stent graft placement for treating CAS of AV access using the cephalic vein as the single outflow provides durable outcomes for patients with AVF.

The Division of Vascular & Endovascular Sciences at Medanta - Gurugram runs a very active Fistula Salvage Clinic. On average 2-3 salvage procedures are performed everyday. Since fistulas are a lifeline for these dialysis dependent patients, maintaining AV-Access is a life saving act.

medanta.org/doctors/dr-tarun-grover

Spotlight

AVF Salvage Clinic @ Medanta

Vascular access offers a way to reach the blood for hemodialysis. The access allows blood to travel through soft tubes to the dialysis machine where it is cleaned as it passes through a special filter, called a dialyzer. An access is placed by a minor surgery.

Vascular access is a patient's lifeline because it makes life-saving hemodialysis treatments possible. Taking good care of the access helps make it last longer.

Vascular-access care is an area of concern, because of a combination of factors such as poor vessel protection, high and prolonged temporary catheter use, shortage of intervention nephrologists, surgeons, and radiologists skilled in creating permanent vascular access, and managing access-related complications.

Fistula Surgery ideally should be performed preemptively 6-8 weeks before initiation of dialysis so that the need for a catheter (neck lines) can be avoided.

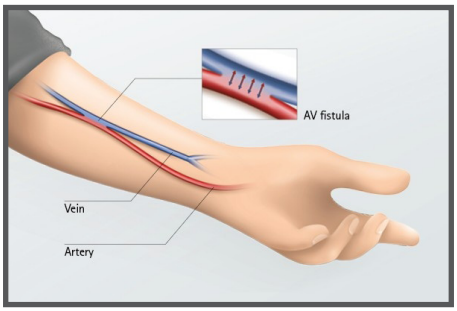

After the surgery it usually takes 6-8 weeks for the high-pressure blood flow from the artery to stretch the vein wall, creating a long-lasting access point that allows the patient to connect to the dialysis machine easily.

AVF Care @ Medanta

Creation and maintenance of AVF is a challenging task. Various issues such as ignorance, lack of knowledge and shortage of trained professionals restrict AVF usage and care. Addressing these challenges Medanta AVF Salvage Clinic works towards improving vascular access intervention.

The clinic was set up by The Division of Vascular & Endovascular Sciences in partnership with The Kidney & Urology Institute at Medanta.

The Medanta AVF Salvage Clinic was established with the philosophy of offering the entire spectrum of therapeutic options to create and salvage AV Access for hemodialysis patients. The Clinic has become a centre of excellence in providing state-of-the-art medical, surgical and endovascular approaches for AVF salvage.

Our extensive experience and expertise in all forms of venous and arterial therapies ensure that the patient receives the best results, faster recovery time, and optimal quality of life. The long-term goals are to enhance awareness of kidney disease and educate clinical professionals.

The clinic's USP is percutaneous minimally invasive treatment options (Angiography, Mechanical

Thrombectomy with Angiojet & Penumbra, Angioplasty, and Catheter placement). It also offers surgical access creation and revision, especially for patients suffering from central venous obstruction.

Patients are advised to visit the clinic if they notice any of these symptoms:

- Prolonged bleeding from the vascular access site post HD
- Signs of infection, such as redness, swelling, soreness, pain, warmth, or pus around the site
- A fever 100.3°F (38.0°C), with chills and rigors or higher during or post HD
- Slow / no flow (thrill) in the fistula
- Numbness or weakness in the hand

medanta.org/doctors/dr-tarun-grover

Medanta@Work

Robotic Radical Prostatectomy

Case of the youngest Indian male

Robotic Assisted Radical Prostatectomy (RARP) is a minimally invasive surgical procedure that uses surgical robotic equipment to remove the entire prostate.
The robotic laparoscopic technique allows surgeons to operate through small ports rather than large incisions, resulting in reduced hospital stays, fewer complications, and shorter recovery times.

RARP at Medanta

RARP is regularly done at Medanta. Over the last 11 years, more than 1000 procedures have been done.

The following case study is of the youngest Indian male who underwent Robotic Radical Prostatectomy for Adenocarcinoma Prostate at Medanta - Gurugram in the year 2016.

36-year-old young male, underwent a routine health check in January 2016 and was detected to have raised serum PSA of 4.6 ng/ml (normally less than 4ng/ml). A digital rectal examination revealed a grade 1 prostate, firm in consistency and non-tender. In the year 2000, his father was diagnosed with Carcinoma Urinary Bladder and had undergone Radical Cystectomy with Neobladder formation. The patient was advised to repeat PSA after one month, which was detected to be 5.2 ng/ml. The urine culture report showed growth of gram negative organism, and for the same, the patient was advised antibiotic course for two weeks and to repeat PSA. Serum PSA done in June 2016 was 6.13ng/ml. Patient was advised Dynamic MRI prostate which revealed areas of mild restricted diffusion in bilateral apical peripheral zones anteriorly appearing hyperintense in DWI and hypointense on ADC map. TRUS guided 12 core prostate biopsy revealed Adenocarcinoma Prostate with perineural invasion. 7 out of 12 cores were positive and Gleason Score was 6 (3 + 3). A review was taken of the biopsy report, which showed similar findings, and 9 out of 12 cores were positive. PSMA PET was done before surgery which showed PSMA avid lesion in both lobes of the prostate with no evidence of uptake elsewhere.

The patient was counseled about all the treatment modalities. Finally, the patient opted for Robotic Radical Prostatectomy. The patient went for cryopreservation as he desired to have another child. Robotic-Assisted Radical Prostatectomy with extended pelvic lymph node dissection and bilateral nerve-sparing surgery was performed on 20 December 2016. The patient was the youngest male in India to undergo RARP surgery. The surgery was uncomplicated, and the patient was

discharged the next day. His final histopathology revealed Adenocarcinoma Prostate, Gleason grade 3+3=6 and no extraprostatic extension. All margins and seminal vesicles were normal. Right pelvic lymphnodes 0/12 and left 0/10 were normal. MCU and catheter removal was done on the seventh day. After the procedure, the patient was fully continent and voiding well. He had complete control of urinary muscles.

Five years following the surgery, the patient is on regular follow-up, and his PSA is undetectable. He continues to lead a normal life, free of cancer and a healthy sexual life.

medanta.org/doctors/dr-narmada-prasad-gupta

Kudos

A MOMENT OF
PRIDE AND HONOUR!

Medanta, Gurugram, has been recognised as the
"Best Multi-Speciality Hospital - National"
at the **Economic Times Healthcare Awards 2021**

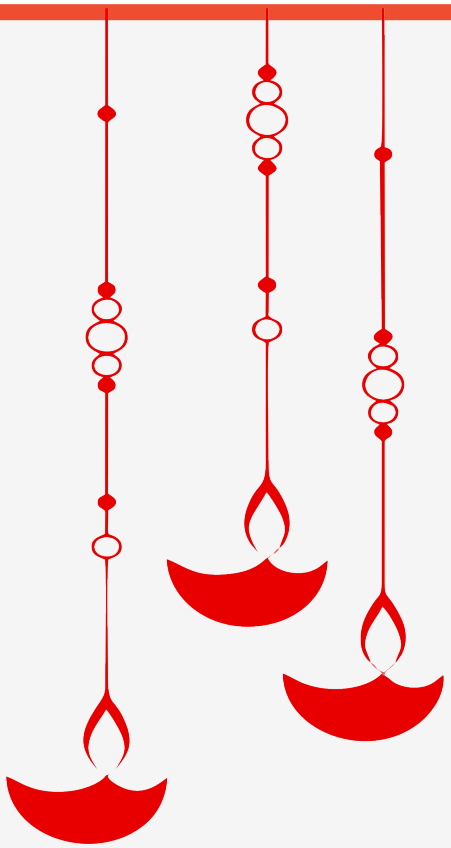

The Light of Hope

Diwali is the festival of hope, happiness and kindness. The festival also symbolizes gratefulness; being thankful to those who've made a difference to our lives.

With its message of all that is auspicious, bright and enduring, on the occasion of Diwali, I would like to convey my heartfelt gratitude to all my colleagues in the healthcare fraternity for tirelessly serving patients with utmost commitment, compassion and care, and wish everyone a healthy and safe festive season.

Keep holding the lights of hope and healing.

Warm regards,
Dr. Naresh Trehan
Chairman & Managing Director, Medanta

THE EXCHANGE

Issue 44
November 2021

Medanta - Gurugram
Sector - 38, Gurugram, Haryana - 122 001 I Tel: +91 124 4141 414 I Fax: +91 124 4834 111
info@medanta.org

Medanta - Lucknow
Sector - A, Pocket - 1, Sushant Golf City,
Amar Shaheed Path, Lucknow 226030 I Tel: +91 522 4505 050

Medanta - Patna
Jaiprabha Medanta Super-Specialty Hospital, Kankarbagh
Main Road, Kankarbagh Colony,
Patna 800 020, Bihar I Tel: +91 82922 22333

Medanta - Ranchi
P.O. Irba, P.S. Ormanjhi, Ranchi - 835 217, Jharkhand
Tel: +91 651 7123 100

Medanta - Indore
Plot No. 8, PU4, Scheme No. 54, Vijaynagar Square,
AB Road, Indore, MP I Tel: +91 731 4747 000

Mediclinic - Delhi
E - 18, Defence Colony, New Delhi - 110 024
Tel: +91 11 4411 4411
mediclinic@medanta.org

Mediclinic Cybercity - Gurugram
UG 15/16, DLF Building 10 C, , DLF Cyber City,
Phase II, Gurugram 122 002 I Tel: +91 124 4141 472
mediclinic.cybercity@medanta.org